

Purtscher Like Retinopathy Complicating Acute Pancreatitis: Rare Case

**Mounir Bouali¹, Othmane El Yamine^{2*}, Meriem Essakhi³, Issam Hamrerras²,
Abdelillah E. I. Bakouri¹, Fatimazahra Bensardi¹, Khalid E. I. Hattabi¹
and Abdelaziz Fadil¹**

¹Department of Visceral Surgical Emergencies, University Hospital Center Ibn Rochd, Faculty of Medicine and Pharmacy, Hassan II University, Casablanca, Morocco.

²Department of General Surgery, University Hospital Center Ibn Rochd, Faculty of Medicine and Pharmacy, Hassan II University, Casablanca, Morocco.

³Department of Ophthalmology, Hospital 20 Aout 1953, Faculty of Medicine and Pharmacy, Hassan II University, Casablanca, Morocco.

Authors' contributions

This work was carried out in collaboration among all authors. Authors MB, OEY, ME and IH designed the study, performed the statistical analysis, wrote the protocol, wrote the first draft of the manuscript, managed the analyses of the study and managed the literature searches. All authors read and approved the final manuscript.

Article Information

Editor(s):

(1) Dr. Syed Faisal Haider, King Saud bin Abdulaziz University for Health Sciences, Saudi Arabia.

Reviewers:

(1) Rahul Gupta, India.

(2) Margarita A. Sazonova, Institute of General Pathology and Pathophysiology, Russia.

Complete Peer review History: <http://www.sdiarticle4.com/review-history/56104>

Case Report

Received 09 February 2020

Accepted 15 April 2020

Published 21 April 2020

ABSTRACT

Acute pancreatitis is an inflammatory process in the pancreas that can affect other distant organs. Ophthalmologic involvement in particular Ischemic retinopathy known as "Purtscher" during acute pancreatitis has been exceptionally associated. Purtscher retinopathy is a retinal vasculopathy most commonly caused by head or chest trauma. The most frequent signs include white ischemic infarcts (cotton-wool spots) and retinal hemorrhages (intraretinal, preretinal, or flame). The signs of ischemic vasculopathy predominate in the interpapillomacular zone. Pathophysiology is not yet fully understood and no treatment has proven effective to date. We report a case of a 48-year-old woman with sudden bilateral loss of vision caused by Purtscher retinopathy in acute pancreatitis.

*Corresponding author: E-mail: othmane.elyamine@gmail.com;

Keywords: *Acute pancreatitis; purtscherlike retinopathy; rare complication.*

ABBREVIATIONS

AP : Acute pancreatitis
PR : Purtscher's Pseudo-retinopathy
CBD : Common bile duct
GB: Gallblader
L : Liver

1. INTRODUCTION

Patients with acute pancreatitis are subject to several complications due to the excessive release of proteolytic enzymes, kinins, lipase, and other active peptides from the inflamed pancreas that can activate complement and produce a process that promotes a multisystem disorder [1]. Purtscher's retinopathy (PR) is a very rare disease with an incidence of 0.24 cases per million per year. It is an occlusive and hemorrhagic vasculopathy, and was originally described as part of the post-traumatic crush syndrome in 1910. It usually occurs after head or chest trauma after a road accident [2], it can be secondary to non-traumatic causes such as autoimmune diseases, renal failure and some viral diseases [3] and exceptionally complicating acute pancreatitis [4]. Purtscher's like retinopathy (PR) is a generally bilateral and asymmetric, rarely unilateral, vision loss resulting from a disorder of choroidal and retinal microcirculation [1,5,6].

The case presented here illustrates through an observation of a bilateral typical ophthalmologic complication, rarely recognized as pseudo retinopathy of acute pancreatitis, which is well documented in the ophthalmologic literature but is not commonly recognized by visceral surgeons.

2. CASE PRESENTATION

It is a 48 year old female patient, with no past medical history, admitted in emergency for cholangitis, with a generalized jaundice over 20 days, associated with a right hypochondrium pain, vomiting, and clinical cholestasis syndrome, with 39°C fever and an alteration of overall health condition. Physical examination found a patient with GCS of 15/15 with normal circulation and respiratory rate. With sensibility in the right hypochondrium. Abdominal ultrasonography revealed hydro cholecystitis associated with gallstone and the common bile duct dilated to 14 mm in diameter containing

microlithiasis. Liver function tests was elevated with total bilirubin of 114 mg/l and conjugated bilirubin of 101 mg/l. After medical treatment of the angiocholitis, the patient underwent endoscopic retrograde Cholangio-pancreatography with sphincterotomy and biliary drainage with insertion of a biliary prosthesis. At D3 postoperative, the patient presented epigastric pain radiating to the back with a lipasemia greater than 13 times normal; an abdominal CT scan is performed; showing stage B pancreatitis (Fig. 1). Complicated two days later, by a sudden bilateral loss of the vision. Ophthalmological examination revealed bilateral visual acuity with positive light perception and intraretinal haemorrhages with cottony nodules in the fund of eye (Fig. 2). The diagnosis of Purtscher's like retinopathy was established. She benefited clinical monitoring, diet restriction and symptoms treatment with parenteral nutrition and vitamin B1, B6 and B12 supplementation combined with anticoagulant treatment and intravenous corticosteroid therapy. The evolution was marked a clinical recovering of the pancreatitis with disappearance of jaundice and normalization of the hepatic assessment with progressive improvement of vision acuity, which passed to 3/10 in the right eye and 4/10 in the left eye with regression of the cottony nodules at the fund of eye.

Ten days after recovery, the patient had a laparoscopic cholecystectomy for gallstones. The patient progressed favorably and discharged on the D10 without complications. The follow up in 1 year was uneventful.

3. DISCUSSION

Acute pancreatitis (AP) is an inflammation of the pancreas, usually resulting from obstruction of the flow of pancreatic secretion. Its incidence is 0.1 to 1 thousand cases/year, and is most often secondary to gallstones in both sexes, or to alcohol. In the standard definition of AP, abdominal pain is a key element in the diagnosis of AP. The pain is usually acute, constant and localized in the epigastric area or upper right quadrant, and often radiates to the back. The results of the physical examination may be variable and may include severe abdominal symptoms [7]. Complications result from the activation of digestive enzymes in the pancreas that activate an interaction chain that promotes the formation of white blood cell emboli that

contribute to vessel damage [1] and may affect other organs located at a distance. Ophthalmological damage has been exceptionally secondary to acute pancreatitis [3]. Purtscher-type pseudoretinopathy with bilateral loss of vision impairment is a rare and serious complication of acute pancreatitis [8]. The association of acute pancreatitis and Purtscher's like retinopathy was first described in 1975 [8]. Since then, only about 15 cases have been reported. Usually retinopathy appears as a consequence of pancreatitis, but one case has been described where visual disturbances preceded the signs of acute pancreatitis [4]. It was found in most cases there was a context of chronic alcoholism and that the presence of this retinopathy was an important prognostic factor in pancreatitis. In the literature, conditions such as liver and pancreas failure have been reported due to synthetic cannabinoids such as Bonzai, describing the association between Purtscher-like retinopathy and substance (Bonzai) abuse [9]. Bilateral PR was presented in 60% of cases and male sex was also a good prognostic factor [10].

The pathophysiology of this disease has not been fully elucidated [1]. Several theories have been advanced since the initial mechanical theory, reserved mainly for traumatic etiologies. The most commonly accepted is micro embolization, which causes pre-capillary arteriolar occlusion and micro vascular infarction

of the nerve fibre layer of the retina, forming cotton wool stains [10]. This could be due to fat emboli, which are known complications of acute pancreatitis, causing retinal ischemia [1,8], or to pancreatic proteases in the systemic circulation, typically described in acute pancreatitis [11].

The two main ophthalmologic signs are cottony nodules and small numbers of flaming hemorrhages, present respectively in 92% and 83% of cases [12]. The circumstances in which cottony nodules can occur in the retina are very numerous, the most frequent cause being diabetic retinopathy, hypertensive retinopathy, Purtscher's syndrome and acute pancreatitis also give rise to emboli that can occlude the retinal arterioles [13]. Purtscher's Fleckens, which are pathognomonic, are present in only 50% of cases. It is a bleaching of the inner retina between arterioles and venules with characteristic sparing of the 50 µm on either side of the retinal arteries and pre-capillary arterioles. These lesions are mainly located at the posterior pole. Atrophy of the pigmentary epithelium and pallor of the optic disc appear late. The final visual prognosis is variable and seems to be related to the initial visual acuity and the speed of disappearance of the initial lesions. It is all the better if the initial visual acuity is good and the lesions of the fundus disappear quickly. Some studies have shown that half of the patients recovered spontaneously one month after the acute episode [6].

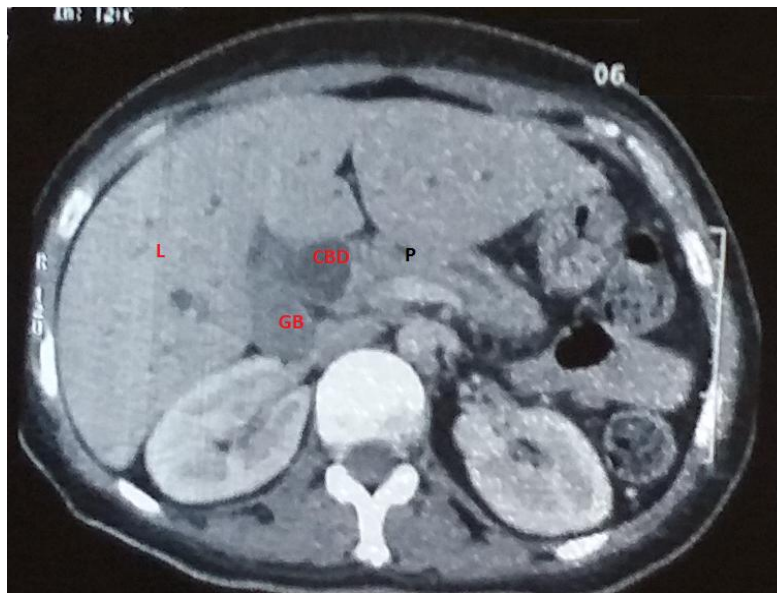


Fig. 1. Abdominal CTscan: Stage B Pancreatitis (P), common bile duct (CBD) dilated (14 mm in diameter) containing microlithiasis. Gallbladder (GB), Liver (L)

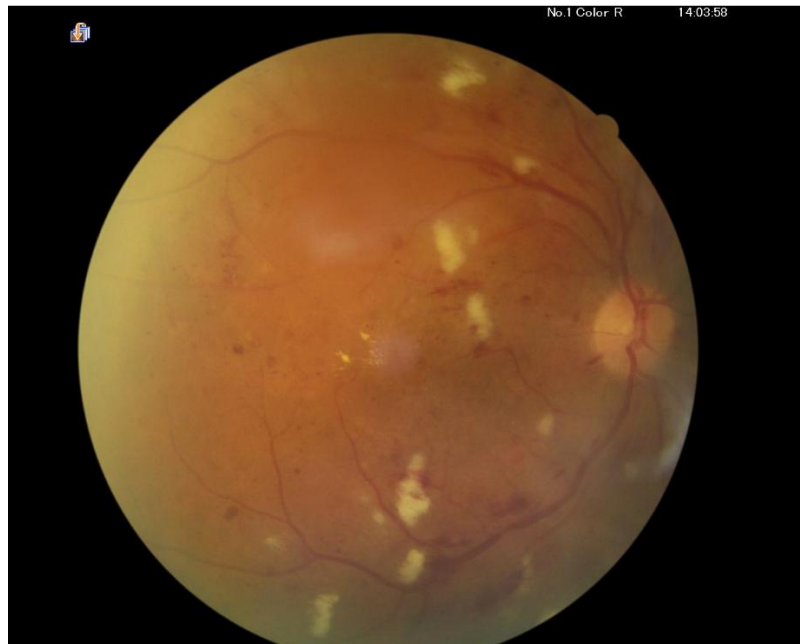

Fig. 2. Fundoscopy (Right eye) multiple cotton-wool spots and intraretinal hemorrhages

There is no consensus on treatment [11] and proposed treatments to restore retinal circulation in the acute phase of occlusion have not been proven efficacy [13]. Some authors propose high-dose intravenous corticosteroids [11], with accelerated visual recovery after use [10]. They inhibit leukocyte aggregation secondary to high-dose complement activation and are thought to play a neuroprotective role. However, at the time of diagnosis, the phenomena of leukocyte aggregation and ischemia are already in place and treatment would only have an impact on the reduction of retinal edema [11]. In the clinical case presented, the recovery of retinal lesions and acute pancreatitis was superposed, and anticoagulant treatment (heparin at hypo-coagulant doses) proved to be indispensable due to the various thrombophlebitis complicating pancreatitis. Anticoagulants can sometimes be combined with vasodilators or systemic corticosteroids. These corticosteroids are useful adjuvants for the reduction of necrotic inflammation could block granulocyte aggregation induced by the C5a fraction of complement [14]. However, their therapeutic use is controversial and more information is needed to determine whether or not corticosteroids may alter the natural history of a patient with Purtscher's pseudo retinopathy [10].

Careful and continuous clinical observation of each patient and treatment of the underlying

etiology may be the most reasonable treatment option taking out the risk of adverse drug reactions [1,10].

4. CONCLUSION

Purtscher's Pseudo-retinopathy (PR) complicating acute pancreatitis (AP) is an exceptional entity. The visual prognosis is variable depending on the degree of macular involvement; sometimes it is severe especially when there is retinal ischemic and edema whose pathophysiology is still discussed today. There are currently no recommendations for the treatment of Purtscher's syndrome and it is based on the treatment of the etiology.

CONSENT

As per international standard or university standard, patient's written consent has been collected and preserved by the author(s).

ETHICAL APPROVAL

As per international standard guideline, written ethical approval has been collected and preserved by the author(s).

COMPETING INTERESTS

Authors have declared that no competing interests exist.

REFERENCES

1. Campo SMA, Gasparri V, Catarinelli G, Sepe M. Acute pancreatitis with Purtscher's retinopathy: Case report and review of the literature. *Dig Liver Dis.* 2000;32(8):729-32.
2. Caplen SM, Madreperla SA. Purtscher's retinopathy: A case report and review. *Am J Emerg Med.* 2008;26(7):836-e1.
3. Niyousha MR, Hassanpoor N, Eftekhari A, Mousvi F. Simultaneous paracentral acute middle maculopathy and purtscher-like retinopathy after acute febrile illness. *Can J Ophthalmol.* 2018;53(5):e184-6.
4. Sanders RJ, Brown GC, Brown A, Gerner EW. Purtscher's retinopathy preceding acute pancreatitis. *Ann Ophthalmol.* 1992; 24(1):19-21.
5. Agrawal A, McKibbin MA. Purtscher's and Purtscher-like Retinopathies: A Review. *SurvOphthalmol.* 2006;51(2):129-36.
6. Agrawal A, McKibbin M. Purtscher's retinopathy: Epidemiology, clinical features and outcome. *Br J Ophthalmol.* 2007;91 (11):1456-1459.
7. Muniraj T, Gajendran M, Thiruvengadam S, Raghuram K, Rao S, Devaraj P. Acute Pancreatitis. *Dis Mon.* 2012;58(3):98-144.
8. Carrera CRL, Pierre LMA, Medina FMC, Pierre-Filho PDT. Purtscher-like retinopathy associated with acute pancreatitis. *Sao Paulo Med J.* 2005;123 (6):289-91.
9. Onaran Z, Akbulut Y, Tursun S, et al. Purtscher-like retinopathy associated with synthetic cannabinoid (Bonzai) Use *Turkish Journal of Ophthalmology.* 2019;49 (2):114-116. DOI: 10.4274/tjo.galenos.2018.67670
10. Miguel AIM, Henriques F, Azevedo LFR, Loureiro AJR, Maberley DAL. Systematic review of Purtscher's and Purtscher-like retinopathies. *Eye.* Janv. 2013;27(1):1-13.
11. Holak H, Holak N, Huzarska M, Holak S. Pathogenesis of Purtscher's retinopathy and Purtscher-like retinopathy. *KlinOcz.* 2007;109(1-3):38-45.
12. Pina JP, Kai ISY, Offret H, Labetoulle M. 525 Pseudo rétinopathie de Purtscher: à propos d'un cas. *J Fr Ophtalmol.* 2008;31: 166.
13. Pascale M, Alain G, Bénédicte D. Pathologie vasculaire du fond d'oeil/ Rétinopathie diabétique. *Lavoisier;* 2014;3:291.
14. Subudhi P, Kanungo S, Subudhi NR. Purtscher's-like retinopathy in acute alcoholic pancreatitis. *Case Reports.* 2016; bcr2016215485.

© 2020 Bouali et al.; This is an Open Access article distributed under the terms of the Creative Commons Attribution License (<http://creativecommons.org/licenses/by/4.0>), which permits unrestricted use, distribution, and reproduction in any medium, provided the original work is properly cited.

Peer-review history:

*The peer review history for this paper can be accessed here:
<http://www.sdiarticle4.com/review-history/56104>*