



Successfully Treated Case of Non-Typhoidal Salmonella Meningitis in an Otherwise Healthy 5 Months Old Infant: A Case Report

Sana Hannan¹ and Abdul Ahad Sohail^{2*}

¹*Department of Pediatrics, The Aga Khan University Hospital, Karachi, Pakistan.*

²*The Aga Khan University Hospital, Karachi, Pakistan.*

Authors' contributions

This work was carried out in collaboration between both authors. Both authors read and approved the final manuscript.

Article Information

DOI: 10.9734/AJPR/2019/v2i3330106

Editor(s):

(1) Dr. Ejellogu, Emeka Uba, Associate Professor, Department of Paediatrics, University of Jos, Jos University Teaching Hospital, Nigeria.

Reviewers:

(1) Xianfeng Zhou, Nanchang Center for Disease Control and Prevention, China.

(2) J. Shindang, College of Health Sciences University of Jos, Nigeria.

(3) Frederico Ribeiro Pires, Hospital da Criança de Brasília José Alencar, Brazil.

Complete Peer review History: <http://www.sdiarticle3.com/review-history/48961>

Case Study

Received 01 March 2019

Accepted 12 May 2019

Published 27 May 2019

ABSTRACT

Acute bacterial meningitis in infants is a medical emergency requiring prompt diagnosis and early institution of empirical antibiotic therapy. Non-typhoidal salmonella (NTS) is a major cause of uncomplicated infectious diarrhoea worldwide; however NTS meningitis is extremely uncommon beyond the neonatal period with very few cases being reported in the literature and has been associated with increased mortality and morbidity with mortality rates of up to 40-70% reported in recent studies. NTS being a facultative intracellular organism does not respond to conventional antibiotic therapy and therefore failure and relapse rates are higher particularly with meningitis. We report a rare case of a five month old infant with non-typhoidal salmonella meningitis who was successfully treated with prolonged duration of antibiotic therapy.

Keywords: Non-typhoidal salmonella; meningitis; infant.

*Corresponding author: Email: abdulahad7@hotmail.com;

1. INTRODUCTION

Acute bacterial meningitis in infants is a medical emergency requiring prompt diagnosis and early institution of empirical antibiotic therapy [1]. Salmonella, a gram negative motile bacilli, has been recognized to cause infectious diarrhoea, enteric fever, focal septic infections, bacteraemia and rarely osteomyelitis and meningitis [2]. They have been broadly classified in two types, Salmonella Typhi (which includes typhi and paratyphi species) and Salmonella Non-Typhi (with 80% of infections being caused by Salmonella typhimurium and Salmonella enteritidis) [3]. Non-typhoidal salmonella (NTS) is a major cause of uncomplicated infectious diarrhea worldwide; however NTS meningitis is extremely uncommon beyond the neonatal period with very few cases being reported in the literature [1,3]. Complicated NTS infections and bacteraemia typically occurs in infants having phagocytic or T-cell dysfunction such as HIV, causing immune-suppression and other conditions such as sickle cell disease causing salmonella osteomyelitis due to vaso-occlusive crisis [1,3].

Non-Typhoidal Salmonella meningitis, although a rare condition in infants of less than six months of age has been associated with increased mortality and morbidity with mortality rates of up to 40-70% reported in recent studies [2,4]. The common complications that have been reported in children with this condition are seizures, hydrocephalus with recent case reports of infants presenting with subdural empyema and brain abscess are found in the literature [5,6]. A study also reported significant developmental delay in 4 out of 9 children who presented with salmonella meningitis [7]. NTS being a facultative intracellular organism does not respond to conventional antibiotic therapy and therefore failure and relapse rates are higher particularly with meningitis. Hence prolonged treatment of 4-6 weeks has been recommended in recent case series with antibiotics that has good intracellular penetration such as third generation cephalosporins, fluoroquinolones and macrolides [1,3,8,9].

We report a case of 5 months old infant, with no other risk factors, that was found to have Salmonella typhimurium meningitis on CSF examination.

2. CASE PRESENTATION

A 5 months old baby boy presented to us with complaints of fever, cough and irritability for past 3 days and respiratory distress for 1 day. Fever

was of low grade type, not-documented and not associated with rigors and chills. Past history of the child was unremarkable. He was born by caesarean section due to low-lying placenta, developmental milestones were according to his age and he was exclusively breastfed. Parents had a non-consanguineous marriage and he had two elder healthy brothers. On examination his weight was 6.7 kilograms, height 64 cm, and occipito-frontal circumference (OFC) of 41cm. His vital signs on presentation were temperature of 38 degrees centigrade, pulse of 181 beats/min, oxygen saturation of 94%, blood pressures of 100/54 mmHg and respiratory rate of 80 breaths /min. On general physical examination he was pale, drowsy, sick looking child with bulging anterior fontanelle. On systemic examination he had bilateral conducting sounds with increased work of breathing. He was initially managed as upper respiratory tract infection and was stabilized with back to back nebulisations and supportive oxygen via nasal prongs which was then gradually weaned off. Chest X-ray was done which showed no evidence of lower respiratory tract infection (Fig. 1).

Ultrasound head was done which showed no evidence of intra-ventricular haemorrhage or hydrocephalus. Then computed tomography scan of head was done which was unremarkable showing normal intra-cranial pressure (Fig. 2). Lumbar puncture was done due to high suspicion of meningitis, which showed murky cerebrospinal fluid (CSF) and when sent for detailed report revealed a very low glucose (<5mg/dl) and high protein count (236 mg/dl) with a raised total leukocyte count of 789/microlitre and 90% polymorphs. Moderate amount of pus cells were also seen. Sample was sent for culture and sensitivity, and broad spectrum intravenous antibiotics that is meropenem and vancomycin were started with a suspicion that the organism may be Streptococcus pneumonia which is a common organism in this age group. Blood culture was also sent which revealed pan-sensitive Salmonella typhimurium. CSF culture also revealed pan-sensitive Salmonella typhimurium (Table 1). Therefore antibiotics were deescalated to intravenous ceftriaxone (100 mg/kg/day) and azithromycin (20mg/kg/day) considering the intracellular nature of the organism.

Lumbar puncture was repeated after 72 hours of antibiotic therapy and CSF sample sent for detailed report revealed a decrease in total leukocyte count of 288/microlitre with 30%

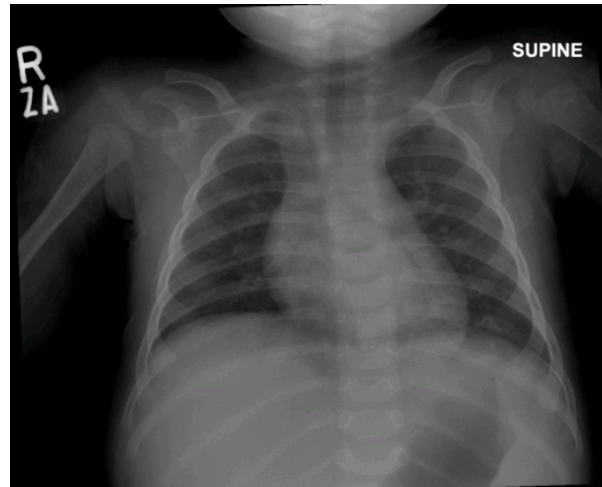


Fig. 1. Chest X-ray of the infant showing no evidence of lower respiratory tract infection

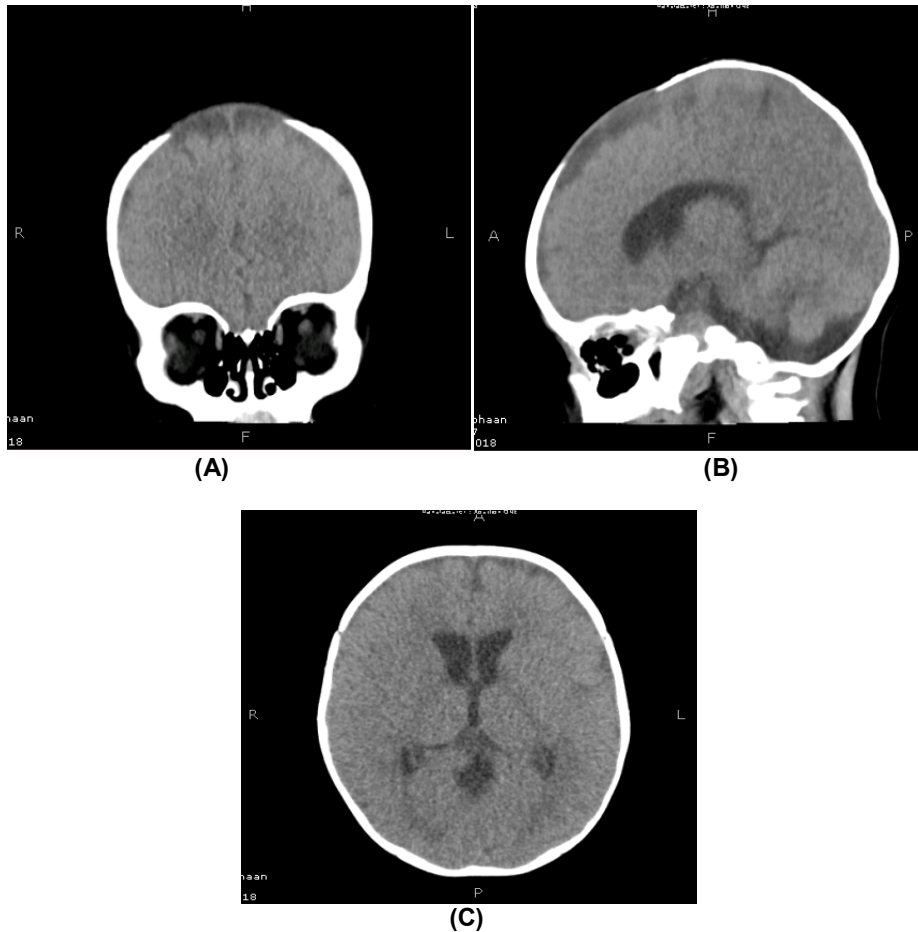


Fig. 2. CT scan of the infant showing bulging anterior fontanelle. No other gross abnormality is identified. (A) Coronal view (B) Sagittal view (C) Axial view with normal lateral and third ventricles, no evidence of raised intracranial pressure

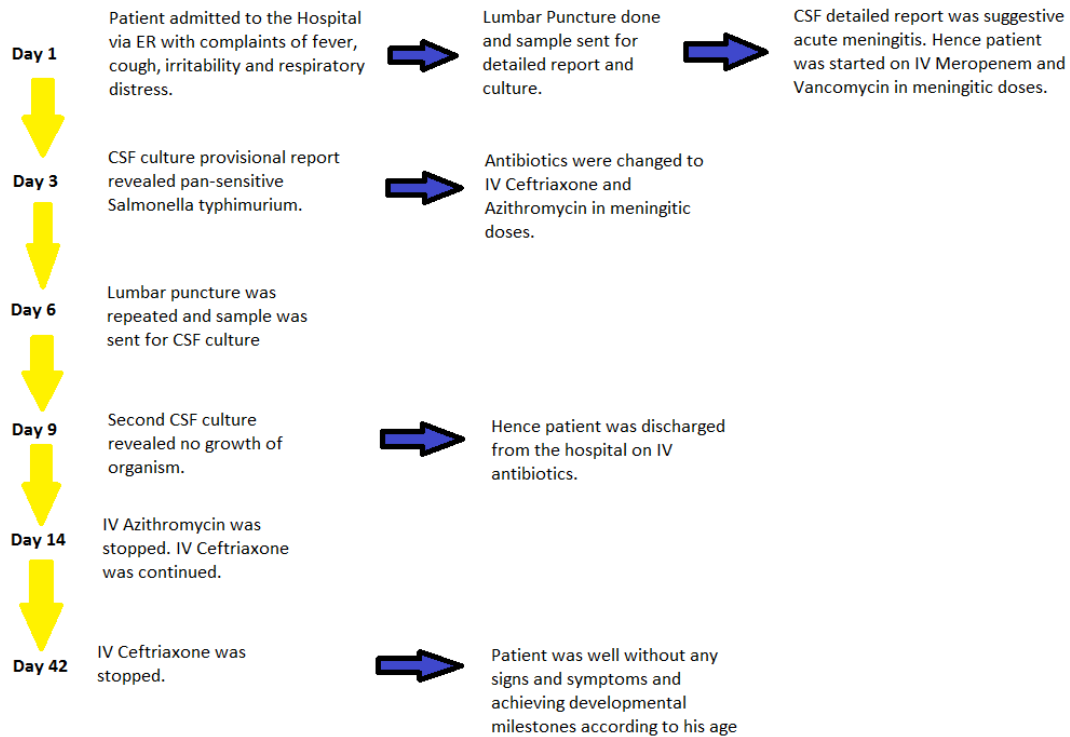

Fig. 3. Timeline depicting the main events in case

polymorphs, a decrease in protein count to 144 mg/dl and few pus cells. Sample was sent for culture and sensitivity which revealed no growth of organism. Patient remained afebrile, his symptoms improved, and he was discharged from hospital on intravenous ceftriaxone which was continued for a total of 42 days and oral azithromycin for a total of 14 days. He was followed up in clinic after 1 week and after 1 month of discharge and on both occasions he remained well without any signs and symptoms achieving developmental milestones according to his age and compliant to antibiotic therapy (Fig. 3).

Table 1. Culture and sensitivity of the CSF

Organism: Salmonella typhimurium	
Antibiotics	S. typhimurium
Ampicillin	S
Ceftriaxone	S
Trimethoprim / Cotrimoxazole	S
Cefixime	S
Ciprofloxacin	I
Chloramphenicol	S
Meropenem	S

S=Sensitive, I=Intermediate

3. DISCUSSION

Salmonella Non-Typhi commonly causes asymptomatic infections, diarrhea, bacteremia and rarely focal septic infections like osteomyelitis and meningitis [10]. The serotypes most frequently isolated from blood and stool cultures are Salmonella typhimurium and enteritidis [3,10]. A recent study in paediatric age group revealed that 24% of children having invasive NTS infections had risk factors such as HIV infection, oncological diseases, malnutrition, pneumonia or low birth weight [10]. Therefore it has been more commonly found in Africa, with a bimodal age distribution in which children aged 6-36 months and elders in the fourth decade of life have been found to be at greatest risk of invasive disease [11]. However a study involving five Asian countries demonstrated Salmonella typhi and para-typhi to be the most common organism being isolated [12]. Salmonella species both typhi and non-typhi usually spread by faeco-oral contamination [1]. Therefore the presence of invasive Salmonella non-typhi disease in a region where S. typhi strains are endemic was a cause for concern as this patient also had no other risk factors and was also on exclusive breast feeding.

Acute bacterial meningitis, a medical emergency requires prompt treatment and early initiation of intravenous antibiotic therapy is required even before the etiology is known [1,2]. Only few case reports have been reported in literature of *Salmonella typhimurium* causing meningitis in immuno-competent infants especially from tropical countries [1,2,6]. A recent case report from India reported a case of acute pyogenic meningitis from *Salmonella typhimurium* leading to subdural empyema and brain abscess [6]. Other case series have reported significant developmental delay in infants presenting with *Salmonella typhimurium* meningitis [7,13]. Besides these, other complications have been reported in literature in these infants including seizures, hydrocephalus, paresis, athetosis and visual disturbances [2]. Therefore a high rate of mortality and morbidity in NTS meningitis makes identification of this organism from cerebrospinal fluid absolutely necessary especially in tropical countries.

Salmonella typhimurium meningitis needs prolonged duration of antibiotics. A recent case reported by Anne et al revealed that *Salmonella typhimurium* meningitis in 5 month old infant treated with intravenous antibiotics for 14 days had a relapse after two weeks of discharge from hospital [1]. Also as it is a facultative intracellular organism and does not respond to conventional empirical antibiotic therapy therefore high rates of treatment failure have been reported with this organism [1,3]. Some studies have recommended a combination therapy of third generation cephalosporins and ciprofloxacin in meningitic doses for a prolonged duration of 4-6 weeks to ensure complete eradication of the organism and to prevent its relapse [6,8,9]. A recent study by Wen et al also adds azithromycin to above regimen because of its effective intracellular penetration for treatment of invasive NTS infections [3]. Also the current recommendation of American Academy of Paediatrics for invasive NTS infection is third generation cephalosporin for 4-6 weeks [14]. Therefore in our case we only continued intravenous ceftriaxone for 6 weeks and azithromycin for 2 weeks as the repeat culture was negative. Wen et al recommends a repeat CSF culture after 48-72 hours and if that is positive continuation of the second antibiotic is recommended for 6 week also [3].

4. CONCLUSION

This case highlights the importance that clinicians should have low index of suspicion for

NTS meningitis in patients presenting with acute bacterial meningitis and showing gram negative bacilli on gram stain. Also it is necessary to isolate the organism as NTS meningitis requires prolong duration of antibiotics to prevent complications and relapse and a brain imaging is recommended to rule out any intracranial collection. Also the child should be followed regularly to look for any signs of developmental delay.

CONSENT

All authors declare that written informed consent was obtained from the patient's guardians for publication of this case report and accompanying images.

ETHICAL APPROVAL

It is not applicable.

COMPETING INTERESTS

Authors have declared that no competing interests exist.

REFERENCES

1. Anne RP, Vaidya PC, Ray P, Singhi PD. *Salmonella typhimurium* meningitis in an infant presenting with recurrent meningitis. The Indian Journal of Pediatrics. 2017; 1-3.
2. Adhikary R, Joshi S, Ramakrishnan M. *Salmonella typhimurium* meningitis in infancy. Indian Journal of Critical Care Medicine: Peer-Reviewed, Official Publication of Indian Society of Critical Care Medicine. 2013;17(6):392.
3. Wen SC, Best E, Nourse C. Non-typhoidal *Salmonella* infections in children: Review of literature and recommendations for management. Journal of Paediatrics and Child Health. 2017;53(10):936-41.
4. Wu HM, Huang WY, Lee ML, Yang AD, Chaou KP, Hsieh LY. Clinical features, acute complications, and outcome of *Salmonella* meningitis in children under one year of age in Taiwan. BMC Infectious Diseases. 2011;11(1):30.
5. Keusch GT. Salmonellosis. In: Fauci AS, Braunwald E, Isselbacher KJ, Wilson JD, Martin JB, Kasper DL, et al., editors. Harrison's Principles of Internal Medicine. 14th Ed. New York: McGraw-Hill. 1998; 950-6.

6. Ploton MC, Gaschignard J, Lemaitre C, Cadennes A, Germanaud D, Poncelet G, Bidet P, Faye A, Basmaci R. Salmonella Typhimurium bacteraemia complicated by meningitis and brain abscess in a 3-month-old boy. *Journal of paediatrics and child health*. 2017;53(2):204-5.
7. Lee WS, Puthuchery SD, Omar A. Salmonella meningitis and its complications in infants. *Journal of Paediatrics and Child Health*. 1999;35(4): 379-82.
8. Price EH, de Louvois J, Workman MR. Antibiotics for Salmonella meningitis in children. *Journal of Antimicrobial Chemotherapy*. 2000;46(5):653-5.
9. Chiu CH, Ou JT. Persistence of Salmonella species in cerebrospinal fluid of patients with meningitis following ceftriaxone therapy. *Clinical Infectious Diseases*. 1999;28(5):1174-5.
10. Barrios P, Badía F, Misa V, Mota MI, Martínez A, Mariño H, Algorta G, Prego J, Pérez MC. A five-year experience with zoonotic Salmonella at a pediatric reference centre. *Revista Chilena de Infectología: Organo Oficial de la Sociedad Chilena de Infectología*. 2017;34(4):359-64.
11. Feasey NA, Dougan G, Kingsley RA, Heyderman RS, Gordon MA. Invasive non-typhoidal salmonella disease: An emerging and neglected tropical disease in Africa. *The Lancet*. 2012;379(9835):2489-99.
12. Khan MI, Ochiai RL, Von Seidlein L, Dong B, Bhattacharya SK, Agtini MD, Bhutta ZA, Do GC, Ali M, Kim DR, Favorov M. Non-typhoidal Salmonella rates in febrile children at sites in five Asian countries. *Tropical Medicine & International Health*. 2010;15(8):960-3.
13. Totan M, Küçüködük Ş. Neonatal Salmonella typhimurium meningitis: Report of a case. *Gazi Medical Journal*. 2001; 12(3).
14. American Academy of Pediatrics. Salmonella infections. In: Pickering LK, Baker CJ, Kimberlin DW, Long SS, eds. *Red Book: 2012 Report of the Committee on Infectious Diseases*. Elk Grove Village: American Academy of Pediatrics. 2012; 635–40.

© 2019 Hannan and Sohail; This is an Open Access article distributed under the terms of the Creative Commons Attribution License (<http://creativecommons.org/licenses/by/4.0>), which permits unrestricted use, distribution, and reproduction in any medium, provided the original work is properly cited.

Peer-review history:

The peer review history for this paper can be accessed here:

<http://www.sdiarticle3.com/review-history/48961>