



Comparative Evaluation of the Influence of Single Preoperative Antibiotic Dose of Amoxicillin (1gm) and Postoperative Antibiotic Dose of Amoxicillin Drug (500mg) Regimen on Postoperative Outcome and Implant Stability in Single Tooth Dental Implant Surgery: Randomized Controlled Trial

Soumya Dudhani^{a*#}, Shwetha Shetty^{a†} and Amit Jagtap^{a‡}

^a Department of Prosthodontics, Crown & Bridge, Dr. D. Y. Patil Dental College & Hospital, D. Y. Patil Vidyapeeth, Pimpri, Pune, India.

Authors' contributions

This work was carried out in collaboration among all authors. All authors read and approved the final manuscript.

Article Information

DOI: 10.9734/JPRI/2021/v33i60B34852

Open Peer Review History:

This journal follows the Advanced Open Peer Review policy. Identity of the Reviewers, Editor(s) and additional Reviewers, peer review comments, different versions of the manuscript, comments of the editors, etc are available here: <https://www.sdiarticle5.com/review-history/81315>

Original Research Article

Received 09 December 2021
Accepted 24 December 2021
Published 25 December 2021

ABSTRACT

Aims: A single blinded randomized controlled trial was conducted to test the efficiency of two antibiotic regimens on post operative outcome and implant stability in single tooth dental implant to overcome the increasing drug resistance due to over prescription of medicines and side effects of the same.

Methodology: 20 participants needing single tooth dental implant were enrolled based on inclusion and exclusion criteria. The participants were randomly assigned into groups. 10 participants in group 1 received only a single preoperative dosage of amoxicillin 1gm which was followed by paracetamol. In group 2, 500mg amoxicillin was given postoperatively followed by a three times a day for 3 days regimen. The postoperative outcome was evaluated based on swelling, post-

[#] Post Graduate student,

[†] Professor & HOD,

[‡] Professor,

*Corresponding author: E-mail: isoumyad@gmail.com;

operative bruising, suppuration and wound dehiscence noticed on 2nd and 7th day postoperatively. ISQ (implant stability quotient) was checked 3 months post implant placement as osseointegration is the main goal of implant placement.

Results: Post-operative bruising, suppuration and wound dehiscence were not noticed in the entire study due to sterile environment during implant placement. When swelling was compared between group 1 and 2 it was statistically insignificant on day 2 (Mann Whitney $u=40.00$, $p=0.383$) and day 7 (Mann Whitney $u=50.00$, $p=01.00$). ISQ (IMPLANT STABILITY QUOTIENT) score in group 1&2 also showed statistically insignificant results ($t=0.00$, $p=1.00$) Which states that there was no significant difference in the stability of implants when single preoperative antibiotic dose of amoxicillin(1gm) and postoperative antibiotic dose of amoxicillin drug(500mg) regimen 3 times a day for 3 days was given.

Conclusion: this study shows that in healthy individual, when single implant is placed in proper sterile environment with routine dental hygiene such as brushing and chlorhexidine mouthwash use by patient, single preoperative dose of amoxicillin 1gm is sufficient for the success of implant. However, considering the limitations of the study, further work is necessary to validate reliability.

No adverse effects were observed in the study

Funding: NIL

Reg no:DYPDCH/EC/648/12/2021

Keywords: Single tooth implants; amoxicillin; paracetamol; swelling; ISQ.

DEFINITIONS, ACRONYMS, ABBREVIATIONS

ISQ : Implant Stability Quotient

RFA : Resonance Frequency Analysis

1. INTRODUCTION

Adhesion of bacteria to implant surface result in infections associated with implants [1]. In spite of high success rates in dental implants, 5–11% of dental implants loss is due to bacterial contamination at time of implant surgery [2]. As the implant surgery is not possible to be executed in an absolute sterile environment and the titanium implant surface being bio inert and micro rough, bacteria readily adheres to the surface of the implant and colonizes to form biofilm.

Biofilms are collection of microorganisms as a self-created extracellular polymeric matrix substances which accounts for majority of the microbial infections in the internal fixation devices. For biofilm formation, the first bacterial attachment within an hour is significant. The bacteria in biofilm which are an easy target to antibiotics such bacteria are resistant to immune responses. Thus, making it strenuous to eradicate them truly once biofilm is formed. The precaution of adhesion and growth of the bacteria is more significant than the removal of the biofilms to avoid implant related infections. [1]. Biofilm formation and antibiotic resistance being time sensitive; different antibiotic protocols

have been developed to prevent the implant related infections. There is evidence, from a systematic review, in ordinary conditions antibiotics can remarkably decrease failure of dental implants.

The recommended antibiotic protocol has been either extended antibiotic administration post-surgery for several days, single dose antibiotic prophylaxis administered before surgery. Drug of choice, its dosage and administration time were the three main variable protocols [3]. However, adjunctive use of antibiotics postoperatively or single dose prophylactically which is beneficial and which antibiotic is the most effective is still unclear [2]. Scientific evidence regarding treatment of dental implant infections and its dosage lead to inconclusive recommendations for clinicians, leading to increase of antibiotic prescription. Due to this, bacterial antibiotic resistance has developed and is becoming a threat to modern healthcare that requires revisiting the antibiotic protocol [4]. Therefore, this study is done to investigate the influence of two different drug regimens on postoperative outcome and implant stability in single tooth implant surgery.

2. MATERIALS AND METHODS

The participants were selected from the outpatient department of Department of Prosthodontics and Crown & Bridge and Implantology, Dr. D.Y. Patil Dental College & Hospital, Pimpri, Pune for this RCT (parallel)

between Jan 2021 and Dec 2021. Inclusion criteria included healthy patients who needed implant rehabilitation with single missing tooth in any one quadrant of maxillary or mandibular arch which requires delayed implant placement. Exclusion criteria included patients with a clinically significant medical history (e.g. Systemic infective disease, heart and vascular disease, liver disease, hematological disease, deficiency of the coagulation, diabetes and neoplastic disease). Patients with medical conditions that required antibiotic premedication and a history of systemic steroid medication or recent systemic antibiotic therapy. Patients having implanted biomaterials in the body (hip or knee prostheses etc.). Immunosuppressed or immunocompromised patients. Patients who received radiotherapy to the head and neck area. Patients in need of bone augmentation procedures concomitant with implant placement. Patients allergic to penicillin. Pregnant or lactating females. Patients already under antibiotic treatment for any other reason. Patients with periapical infection of the tooth adjacent to the implant site.

The selected participants were randomly grouped into two groups: Group 1: – a single antibiotic preoperative dose of amoxicillin (1gm) before surgery (n = 10) and Group 2: postoperative antibiotic regimen of amoxicillin (500mg) drug post-surgery (three times a day for 3 days) (n = 10) based on inclusion and exclusion criteria. Verbal and physical consent were taken from the patients prior to the participation in the study. Patients were informed about the surgical procedure, the nature of the study was given in written and for decision making for participation in the study, one week or more was given. An informed consent was obtained before the surgery.

A detailed case history and clinical examination was recorded. CBCT and panoramic radiographs were made. Preoperative extra oral and intraoral photographs were taken (Fig 1.). Pre-operative preliminary maxillary and mandibular impressions were made using alginate Impression Material (Imprint dust free, DPI, India). The impressions were poured with Dental stone (Kalabhai, India) for diagnostic cast and the same were mounted onto a mean value Articulater(RKD INDIA) using intraoral bite registration in maximum intercuspal position [5]. The choice of implant size was made on the basis of measurements on the diagnostic cast

and CBCT by the operating clinician. Patients were randomly allocated to two different groups:

1) Group 1 -a single antibiotic dose 1gm amoxicillin(Alkem laboratories, India) 1hr prior to surgery; followed by administration of paracetamol 500 mg(Cipla, India) tablets immediately post-surgery and following 2 days, as required to a maximum of 4 g/day) Group 2 – postoperative antibiotic dose- 500 mg amoxicillin post-surgery and 500 mg amoxicillin thrice a day for the following 3 days, administration of paracetamol 500 mg tablets immediately post-surgery and following 3 days, as required to a maximum of 4 g/day. In Group 1, 1gm amoxicillin was given orally 1 hour prior to implant placement. All patients were draped. Betadine solution (Win Medicare Pvt Ltd, India)was painted around the mouth. The patient was asked to rinse for at least 60 seconds with a chlorhexidine 0.2% (ICPA Health Products Ltd.,India) mouth rinse prior to the surgery. The local anesthesia, lidocaine 2% with adrenaline 1:200000 (Neon Laboratories Ltd, India)was administered. A mucoperiosteal flap was raised after incision using blade no. 15 following adequate local anesthesia at the site (Fig 2.). Incision was based on by the local anatomy which involves the bone present at surgical site, peripheral tooth roots and aesthetics. Under copious saline irrigation, sequential osteotomies were then carried out (Fig 3). Opting for a two stage approach, implant (DENTIUM/GENESIS/SYNA) was inserted and cover screw was placed (Fig 4 &5). Flap closure of surgical site was done in a tension free manner. All the patients were administered with paracetamol 500 mg tablets immediately post-surgery and following 3 days as required to a maximum of 4 g/day, to reduce the effect of independent variables. Post-operative instructions for the first postoperative week starting from the following day of the surgery include ice pack application, use of chlorhexidine 0.2% mouthwash 4–5 times daily, soft and cold diet and refrain from brushing the area of surgery. Post-operative care standardized forms and instructions were given personally to all participants [3]. For, GROUP 2 postoperative antibiotics, consisting of amoxicillin 500mg after the surgery and 500m g thrice a day for 3 days following surgery was prescribed.

Postoperative outcome showing: post-operative bruising, suppuration and wound dehiscence will be recorded on the 2nd and 7th days by the

same examiner and the supervisor using Boolean Variables. • 0 = None • 1 = Present .

Post-operative swelling was being graded by the same examiner on the 2nd and 7th days as • 0 = No swelling • 1 = Mild swelling • 2 = Moderate swelling • 3 = Severe swelling.

Implant stability: Implant stability was recorded using Penguin RFA (GOLDENDENT USA) device during the 2nd stage surgery after 3months by the same examiner and the supervisor (Fig 6). The instrument measures the frequency of the

vibration and translates it to an ISQ scale value between 1 and 99. The higher the ISQ value, the better the stability. → ISQ Scale: ISQ greater than 65 indicates a very high stability and suggests successful implant. ISQ below 55 indicates low stability which suggests either the loading to be delayed or indicate potential failure.

The postoperative outcome was observed by supervisor and the operator and the mean would be recorded for minimizing the bias in the study.

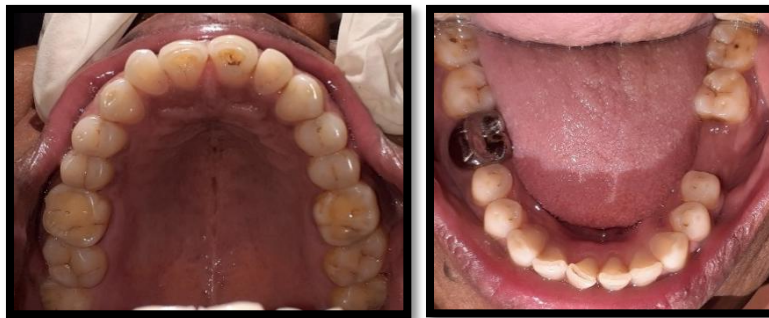

Fig. 1. Intraoral pictures

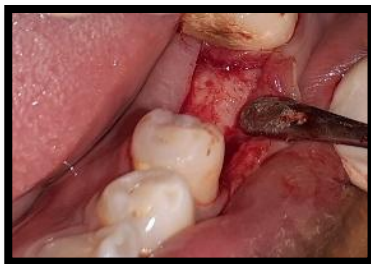

Fig. 2. Midcrestal incision

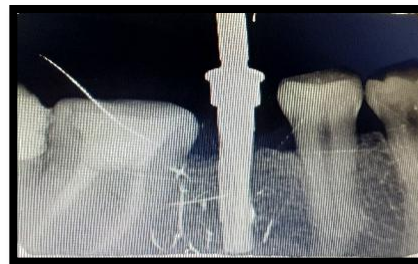


Fig. 3. pilot drill

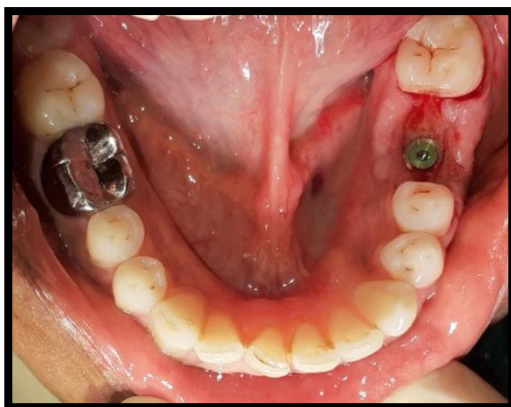

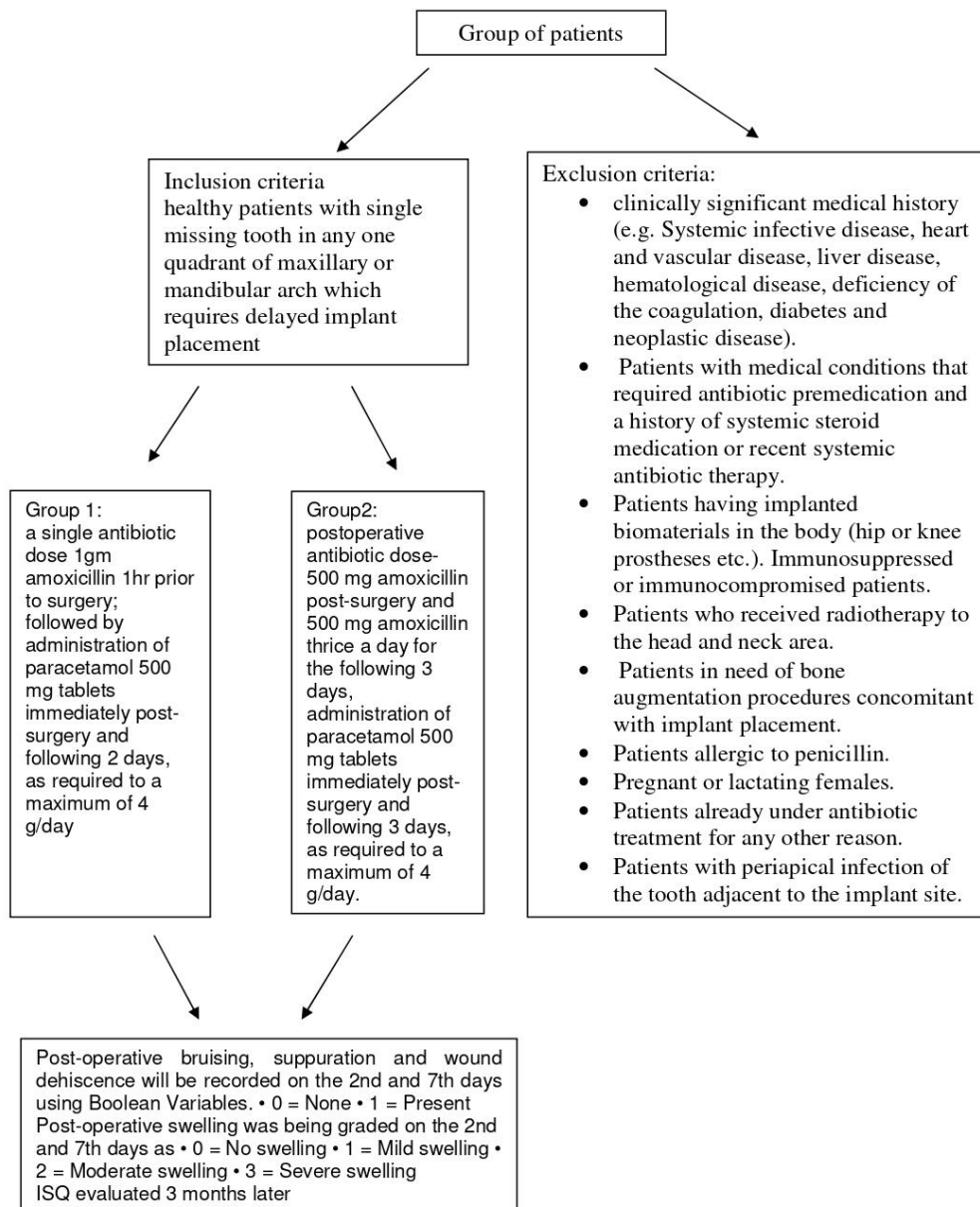
Fig. 4. Implant placement

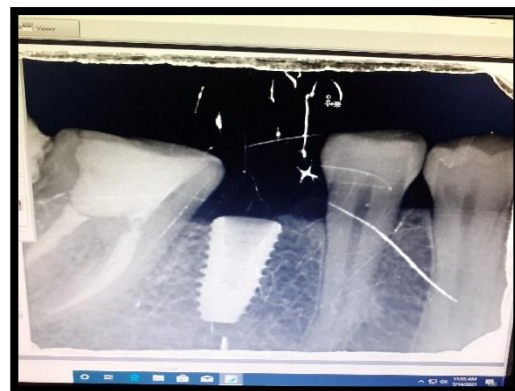

Fig. 5. Radiographic evaluation after implant placement



Fig. 6. ISQ checking after 3 months of implant placement



Statistical analysis: considering the nature of study Wilcoxon signed-rank test and Mann–Whitney U test were carried out.

Observations:

Chart 1. Pre operative single dose amoxicillin

Sr. No	Post-Operative Bruising		Suppuration		Wound Dehiscence		Swelling		ISQ
	2nd	7th	2nd	7th	2nd	7th	2nd	7th	
1	0	0	0	0	0	0	1	0	79
2	0	0	0	0	0	0	2	1	80
3	0	0	0	0	0	0	2	0	82
4	0	0	0	0	0	0	1	0	78
5	0	0	0	0	0	0	2	0	81
6	0	0	0	0	0	0	1	0	80
7	0	0	0	0	0	0	2	1	81
8	0	0	0	0	0	0	2	0	85
9	0	0	0	0	0	0	1	0	84
10	0	0	0	0	0	0	2	0	79

Chart 2. Postoperative antibiotic dose- 500 mg amoxicillin post-surgery and 500 mg amoxicillin thrice a day for the following 3 days

Sr. No	Post-Operative Bruising		Suppuration		Wound Dehiscence		Swelling		ISQ
	2nd	7th	2nd	7th	2nd	7th	2nd	7th	
1	0	0	0	0	0	0	1	0	78
2	0	0	0	0	0	0	2	1	80
3	0	0	0	0	0	0	1	0	82
4	0	0	0	0	0	0	2	1	81
5	0	0	0	0	0	0	2	0	80
6	0	0	0	0	0	0	2	1	85
7	0	0	0	0	0	0	1	0	84
8	0	0	0	0	0	0	1	0	79
9	0	0	0	0	0	0	1	0	79
10	0	0	0	0	0	0	1	0	81

3. RESULTS

The results obtained on the 2nd and 7th days are tabulated for statistical analysis which states post-operative swelling were be graded by the same examiner as

- 0 = No swelling
- 1 = Mild swelling
- 2 = Moderate swelling
- 3 = Severe swelling.

The post-operative bruising, suppuration and wound dehiscence recorded on the 2nd and 7th days by the same examiner using Boolean Variables.

(• 0 = None • 1 = Present)was insignificant as no post-operative bruising, suppuration and wound dehiscence was recorded in the samples in the entire study.

Comparison of mean rank score between group 1 and 2 showed statistically insignificant results

on day 2 (Mann whitney $u=40.00$, $p=0.383$) and day 7 (Mann whitney $u=50.00$, $p=01.00$)

This states that there was no remarkable difference in the postoperative swelling seen on 2nd and 7th day after implant placement when single preoperative antibiotic dose of amoxicillin(1g) and postoperative antibiotic dose of amoxicillin drug(500mg) regimen 3 times a day for 3 days was given.

Comparison of mean score in group 1 between swelling day 2 and 7 showed statistically significant results on day 2 and day 7 (wilcoxon sign rank= 2.739 , $p=0.006$) Which states that there was significant difference in the postoperative swelling seen on 2nd and 7th day after implant placement when single preoperative antibiotic dose of amoxicillin(1g) was given. Post-operative inflammatory reaction is obvious after surgical trauma and as seen in the result it subsides eventually.

Table 1. Comparison of mean rank score between group 1 and 2 on day 2 and day 7

	grp	N	Mean Rank	Mann-Whitney U	P value
swelling2day	1.00	10	11.50	40.000	.383
	2.00	10	9.50		
	Total	20			
swelling7day	1.00	10	10.50	50.000	1.000
	2.00	10	10.50		
	Total	20			

Table 2. Comparison of mean score in group 1 between swelling day 2 and 7

Paired Samples Statistics						
GROUP1		Mean	N	Std. Deviation	Wilcoxon sign rank test	P value
Pair 1	swelling2day	1.6000	10	.51640	2.739	0.006
	swelling7day	.3000	10	.48305		

Table 3. Comparison of mean score in group 2 between swelling day 2 and 7

Paired Samples Statistics						
Group 2		Mean	N	Std. Deviation	Wilcoxon sign rank test	P value
Pair 1	swelling2day	1.4000	10	.51640	3.051	0.04
	swelling7day	.3000	10	.48305		

Table 4. Comparison of mean ISQ score in group 1&2

	grp	N	Mean	Std. Deviation	Mean diff	T	P value
isq	1.00	10	80.9000	2.23358	0.00	0.00	1.00
	2.00	10	80.9000	2.23358			

Comparison of mean score in group 2 between swelling day 2 and 7 showed statistically significant results on day 2 and day 7 (wilcoxon sign rank=2.89, p=0.0.04).

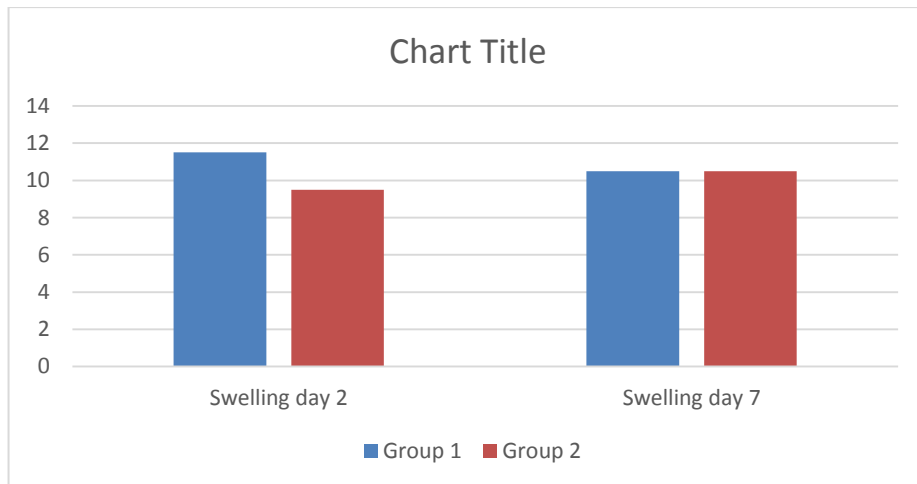
Which states that there was significant difference in the postoperative swelling seen on 2nd and 7th day after implant placement when postoperative antibiotic dose of amoxicillin drug(500mg) regimen was given. Post-operative inflammatory reaction is obvious after surgical trauma and as seen in the result it subsides eventually.

Group statistics: Comparison of mean ISQ (IMPLANT STABILITY QUOTIENT) score in group 1&2 showed statistically insignificant results (t=0.00, p=1.00) Which states that there was no significant difference in the stability of implants when single preoperative antibiotic dose of amoxicillin(1g) and postoperative antibiotic dose of amoxicillin drug(500mg) regimen 3 times a day for 3 days was given.

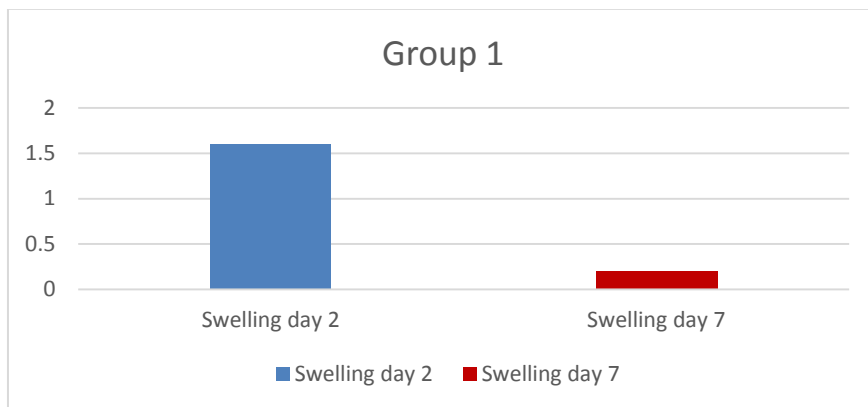
According to the observation, as no post-operative bruising, suppuration and wound dehiscence was noted in the samples in the entire study and it was not compared. The postoperative swelling seen on 2nd day of implant placement was observed significant in both groups which subsided by 7th day after implant placement. There was no remarkable difference in the postoperative swelling seen on 2nd and 7th day after implant placement when single preoperative antibiotic dose of amoxicillin(1g) and postoperative antibiotic dose of amoxicillin drug(500mg) regimen was given.

The data was statistically analyzed using Wilcoxon signed-rank test and Mann-Whitney U test. There was no remarkable difference in the stability of implants when single preoperative antibiotic dose of amoxicillin(1g) and postoperative antibiotic dose of amoxicillin drug(500mg) regimen 3 times a day for 3 days was given.

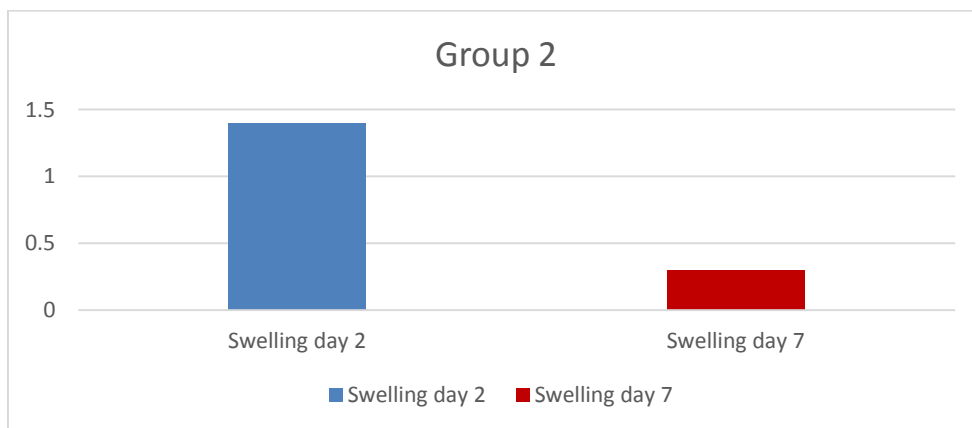
Graphs:



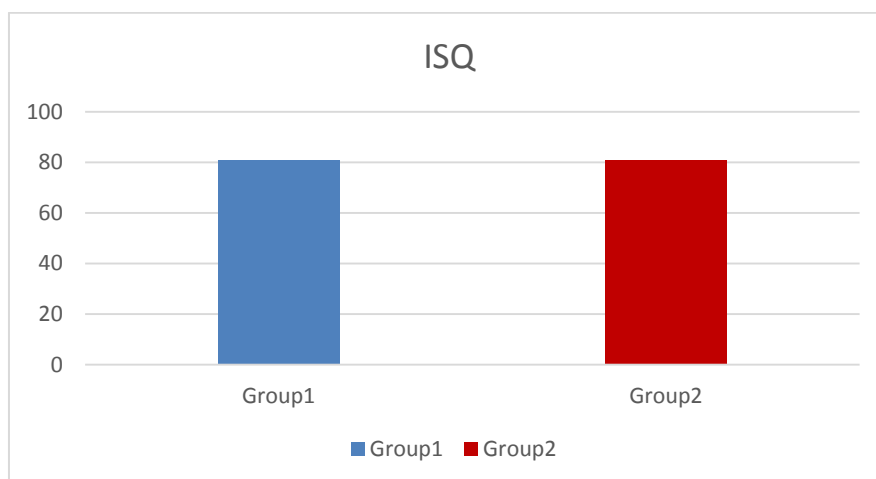
Graph 1. Comparison of postoperative swelling seen on 2nd and 7th day after implant placement when single preoperative antibiotic dose of amoxicillin (1g) and postoperative antibiotic dose of amoxicillin drug(500mg) regimen was given



Graph 2. Comparison of postoperative swelling seen on 2nd and 7th day after implant placement when single preoperative antibiotic dose of amoxicillin (1g) was given



Graph 3. Comparison of postoperative swelling seen on 2nd and 7th day after implant placement when postoperative antibiotic dose of amoxicillin drug (500mg) regimen was given



Graph 4. Comparison of implant stability after implant placement when single preoperative antibiotic dose of amoxicillin (1g) and postoperative antibiotic dose of amoxicillin drug(500mg) regimen was given

4. DISCUSSION

Dental implant is routinely practiced as a definitive solution to missing teeth due to its predictable outcome. But failures do occur and one of the major causes for failure of implants is perioperative bacterial contamination. Rapid colonization of bacteria is seen in peri-implant sulcus after implant placement is done, which is difficult to treat [6]. The local defense system, in the early phase of implant placement is severely disturbed by the surgical trauma making it susceptible for causing infection. Even after tissue healing is complete, due to small number of blood vessels in implant tissue interface, dental implant are vulnerable to bacterial contamination [7].

Antibiotic prophylaxis plays a crucial step in preventing implant failures in such cases. Periimplant region is likely to harbour a certain strains of bacterial colonies which include: streptococci, anaerobic Gram positive cocci, and anaerobic gram negative rods. Thus, the choice of antibiotic for the faster wound healing in these cases should be bactericidal and of low toxicity, example of such antibiotic is amoxicillin [8].

A variation of antibiotic regimens of amoxicillin used prophylactically have been suggested to reduce infections post implant placement. The two regimes compared in this study are a single preoperative dose of 1gm and a regime of 500mg thrice daily for 3 days postoperatively.

Latest protocols recommend, if antibiotics have to be used for prophylactically in a healthy individual with no co-morbidities, it should be short termed. Antibiotic concentration in the blood would prevent proliferation and dissemination of bacteria, thereby preventing the initiation of infection at surgical wound [7]. Preoperative single dose of amoxicillin is sufficient for prevention of the early implant failure, thus avoiding long-term antibiotic administration according to the reviews based on randomized controlled trial. Study by Daniel M. Laskin et al. [9] also shows that use of antibiotics before operating significantly enhances the dental implant survival overall, including the early stages [9]. Studies by Dent et al. [9] Laskin et al [9], Pyysalo *et al*, Ata-Ali *et al* and Escalante *et al* also support this observation [11] The Cochrane review concluded a statistically significant difference in implant survival when prophylactic antibiotics used before surgery as compared to placebos (Esposito et al. 2010). These results are in agreement with those of the present study. The mechanism of action of antibiotics before surgery and its effect are unknown. Maintenance of local aseptic environment during the implant placement and in the immediate perioperative period is crucial for faster healing and, ultimately leading to osseointegration [10-15].

However, some studies such as by Ahmad and Saad suggested administration of preventive antibiotics with attention and only when appropriately indicated, not just as a general measure [8].

Post-operative antibiotic regime remains open-ended and can be based on procedural outcomes during and after completion of the operation [16].

The only analgesic selected to be used by participants in order to standardise and improve sureness of the results, paracetamol was used as post-operative pain medication. It has been shown to be a potent pain reliever with low chances of side effects (Moore et al. 2000). It has also been proved in a number of clinical trials to be an excellent analgesic for post-operative dental pain control (Bentley & Head 1987; Mehlisch 1990; Kiersch et al. 1994 [17].

The events in post-operative morbidity, they include post-operative swelling, bruising, suppuration and wound dehiscence during the early wound-healing period which may further develop into deprivation of bone and tissue at the implant site and implant failure in long term [6]. It was evaluated 2 and 7 days post-operatively, for any of the four outcome variables, no statistically remarkable variance were found at either 2 or 7 days post-operatively except swelling which was evident on 2nd day post operatively and gradually reduced by 7th day as seen in table 1, 2 & 3 (Graph 1,2,3). Our study shows post-operative bruising, suppuration and wound dehiscence can be avoided by maintaining sterile environment and correct implant placement.

In long term, post-operative bruising, suppuration and wound dehiscence can progress to bone loss if not intervened. Implant failure is mobility in implant that has failed to osseointegrate. To check this, RFA (resonance frequency analysis) has been used to assess the implant primary stability. To determine the period for practical implant loading, an indirect indicator i.e the Implant stability measurements (ISQ) are used. Possible implant failure stability over time can also be determined by it.

There was no remarkable difference in the implant stability quotient when single preoperative antibiotic dose of amoxicillin (1gm) and postoperative antibiotic dose of amoxicillin drug (500mg) (Table 4 & Graph 4)

Thus, there is no substantial difference in outcome of the implants placed when single preoperative antibiotic dose of amoxicillin (1gm) and postoperative antibiotic dose of amoxicillin drug (500mg) regimen was given.

As an adjunct to antibiotics administration, Chlorhexidine digluconate (CHX) mouthwash rinse has been acknowledged to be a fruitful aid in accelerating the healing and lowering complications of surgery due to its high substantivity, especially when used in when used routinely in the peri-operative period [7]. When compared on implant survival rates of implants placed with pre-operative antibiotics and without preoperative antibiotic coverage with chlorhexidine being common factor, the implant survival improving by 5.8% in first group and by 7.8% in the later [18-19].

Other important factors contributing to the success rates of implants include management of the operatory, expertise of the surgeon in surgery and sterilization protocol and the medical health of the patient. Anatomic, prosthetic and patient factors such as early loading of the implant and absence of adequate alveolar bone, and hygiene practices raise the chances of infection postoperatively. Antibiotics should not be an excuse for inappropriate technique [20].

5. CONCLUSION

Within limitations of this in vivo study and considering the complex multistep study design, limited number of participants and referring to single tooth implant, the following conclusion could be drawn: Post-operative bruising, suppuration and wound dehiscence can be avoided by maintaining sterile environment and correct implant placement. There was no remarkable difference in the postoperative swelling seen on 2nd and 7th day after implant placement when single preoperative antibiotic dose of amoxicillin (1gm) and postoperative antibiotic dose of amoxicillin drug (500mg) regimen was given. There was remarkable postoperative swelling seen on 2nd day as compared to 7th day after implant placement in both groups when single preoperative antibiotic dose of amoxicillin (1gm) and postoperative antibiotic dose of amoxicillin drug (500mg) regimen was given. There was no remarkable difference in the implant stability quotient when single preoperative antibiotic dose of amoxicillin (1gm) and postoperative antibiotic dose of amoxicillin drug (500mg) was given.

CONSENT

All authors declare that 'written informed consent was obtained from the patient (or other approved parties) for publication of this case report and

accompanying images. A copy of the written consent is available for review by the Editorial office/Chief Editor/Editorial Board members of this journal.

ETHICAL APPROVAL

All authors hereby declare that all experiments have been examined and approved by the appropriate ethics committee and have therefore been performed in accordance with the ethical standards laid down in the 1964 Declaration of Helsinki

ACKNOWLEDGEMENTS

I take pride in acknowledging the insightful suggestions, encouragement and immense knowledge of Dr. Amit Jagtap, Professor and Head, Department of Prosthodontics and Crown & Bridge. His vision of achieving perfection in everything has helped me to strive for the best.

COMPETING INTERESTS

Authors have declared that no competing interests exist.

REFERENCES

1. Pan C, Zhou Z, Yu X. Coatings as the useful drug delivery system for the prevention of implant-related infections. *J Orthop Surg Res.* 2018;13:220. Available:<https://doi.org/10.1186/s13018-018-0930-y>
2. Paolo G. Arduino, Federico Tirone, Emanuele Schiorlin, Marco Esposito Single preoperative dose of prophylactic amoxicillin versus a 2-day postoperative course in dental implant surgery: A two-centre randomised controlled trial *Eur J Oral Implantol.* 2015;8(2):143–149.
3. Nolan R, Kemmoona M, Polyzois I, Claffey N. The influence of prophylactic antibiotic administration on post-operative morbidity in dental implant surgery. A prospective double blind randomized controlled clinical trial. *Clin. Oral Impl. Res.* 2014;25:252–259. DOI: 10.1111/clr.12124
4. Dalia Khalil, Bodil Lund and Margareta Hultin Antibiotic in implant dentistry *Dental Implantology and Biomaterial.* 2016;20-38.
5. Resnik RR, Misch C. Prophylactic antibiotic regimens in oral implantology: rationale and protocol. *Implant Dent.* 2008;17(2):142-50. DOI:10.1097/ID.0b013e3181752b09. PMID: 18545045.
6. Koyanagi T, Sakamoto M, Takeuchi Y, Ohkuma M, Izumi Y. Analysis of microbiota associated with peri-implantitis using 16S rRNA gene clone library. *J Oral Microbiol.* 2010;2. DOI:10.3402/jom.v2i0.5104. PMID: 21523229; PMCID: PMC3084566.
7. Zhao L, Chu PK, Zhang Y, Wu Z. Antibacterial coatings on titanium implants. *J Biomed Mater Res B Appl Biomater.* 2009;91(1):470-80. DOI:10.1002/jbm.b.31463. PMID: 19637369.
8. Ahmad N, Saad N. Effects of antibiotics on dental implants: a review. *J Clin Med Res.* 2012;4(1):1-6. DOI:10.4021/jocmr658w. Epub 2012 Jan 17. PMID: 22383920; PMCID: PMC3279494. References Page 34
9. Laskin DM, Dent CD, Morris HF, Ochi S, Olson JW. The influence of preoperative antibiotics on success of endosseous implants at 36 months. *Ann Periodontol.* 2000;5(1):166-74. DOI: 10.1902/annals.2000.5.1.166. PMID: 11885177.
10. Esposito M, Grusovin MG, Worthington HV. Interventions for replacing missing teeth: antibiotics at dental implant placement to prevent complications. *Cochrane Database Syst Rev.* 2013;(7):CD004152. DOI: 10.1002/14651858.CD004152.pub4. PMID: 23904048; PMCID: PMC6786879.
11. Kim A, Abdelhay N, Levin L. Et al. Antibiotic prophylaxis for implant placement: a systematic review of effects on reduction of implant failure. *Br Dent J.* 2020;228:943–951. Available: <https://doi.org/10.1038/s41415-020-1649-9>
12. Gynther GW, Köndell PA, Moberg LE, Heimdahl A. Dental implant installation without antibiotic prophylaxis. *Oral Surg Oral Med Oral Pathol Oral Radiol Endod.* 1998;85(5):509-11. DOI:10.1016/s1079-2104(98)90281-5. PMID: 9619664.
13. Lawler B, Sambrook PJ, Goss AN. Antibiotic prophylaxis for dentoalveolar

- surgery: is it indicated? Aust Dent J. 2005;50(4 Suppl 2):S54-9.
DOI:10.1111/j.1834-7819.2005.tb00387.x.
PMID: 16416719.
14. Mazzocchi, Alberto & Passi, Luca & Moretti, Roberto. Retrospective Analysis of 736 Implants Inserted Without Antibiotic Therapy. Journal of oral and maxillofacial surgery: official journal of the American Association of Oral and Maxillofacial Surgeons. 2007;65:2321-3.
DOI: 10.1016/j.joms.2007.06.620.
 15. Park J, Tennant M, Walsh LJ, Kruger E. Is there a consensus on antibiotic usage for dental implant placement in healthy patients? Aust Dent J. 2018;63(1):25-33.
DOI: 10.1111/adj.12535. Epub 2017 Jul 25. PMID: 28543332.
 16. Caiazzo A, Casavecchia P, Barone A, Brugnami F. A pilot study to determine the effectiveness of different amoxicillin regimens in implant surgery. J Oral Implantol. 2011;37(6):691-6.
DOI:10.1563/AAID-JOI-D-09-00134.1.
Epub 2010 Jun 16. PMID: 20553148.
References Page 35
 17. Esposito M, Coulthard P, Oliver R, Thomsen P, Worthington HV. Antibiotics to prevent complications following dental implant treatment. Cochrane Database Syst Rev. 2003;(3):CD004152.
DOI:10.1002/14651858.CD004152.
Update in: Cochrane Database Syst Rev. 2008;(3): CD004152. PMID: 12918006.
 18. Abraham HM, Philip JM, Kruppa J, Jain AR, Krishnan CJV. Use of Chlorhexidine in Implant Dentistry. Biomed Pharmacol J. 2015;8(October Spl Edition)
 19. Chye RML, Perrotti V, Piattelli A, Iaculli F, Quaranta A. Effectiveness of Different Commercial Chlorhexidine-Based Mouthwashes After Periodontal and Implant Surgery: A Systematic Review. Implant Dent. 2019;28(1):74-85.
DOI: 10.1097/ID.0000000000000854.
PMID: 30648980
 20. Bernabeu-Mira JC, Peñarrocha-Diago M, Peñarrocha-Oltra D. Prescription of Antibiotic Prophylaxis for Dental Implant Surgery in Healthy Patients: A Systematic Review of Survey-Based Studies. Front Pharmacol. 2021;11:588333.
DOI: 10.3389/fphar.2020.588333.
PMID: 33643035;
PMCID: PMC7902906

© 2021 Dudhani et al.; This is an Open Access article distributed under the terms of the Creative Commons Attribution License (<http://creativecommons.org/licenses/by/4.0>), which permits unrestricted use, distribution, and reproduction in any medium, provided the original work is properly cited.

Peer-review history:

*The peer review history for this paper can be accessed here:
<https://www.sdiarticle5.com/review-history/81315>*